

NADINE D. FEIL
ANDREAS FILIPPI

¹ Department of Oral Surgery, Oral Radiology and Oral Medicine and Center of Dental Traumatology, University Center for Dental Medicine Basel, University of Basel, Switzerland

CORRESPONDENCE

Prof. Dr. med. dent.
 Andreas Filippi
 Klinik für Zahnärztliche Chirurgie, –Radiologie, Mund- und Kieferheilkunde und Zahnunfallzentrum, Universitäres Zentrum für Zahnmedizin Basel
 Hebelstrasse 3
 CH-4056 Basel
 Tel. +41 61 267 26 11
 Fax +41 61 267 26 07
 E-mail: andreas.filippi@unibas.ch

SWISS DENTAL JOURNAL SSO 126:
 886–891 (2016)
 Accepted for publication:
 8 March 2016

Frequency of fissured tongue (lingua plicata) as a function of age

KEYWORDS

lingua plicata,
 age dependence,
 fissured tongue,
 tongue diagnostics

SUMMARY

Fissured tongue (lingua plicata; LP) is a mostly asymptomatic condition characterized by grooves and fissures of varying depth on the dorsal surface of the tongue. Most reports in the literature indicate a prevalence of 10–20%, although there is marked variation. On the basis of 1,000 patients (n=465 males, n=535 females), this study examined the association between LP and age as well as further influencing factors. Participants completed a questionnaire comprising information regarding gender, age, alcohol and tobacco consumption, possibly existing removable den-

tures, and potential mouth burning. Subsequently, photographs of the protruded tongue were taken and examined by two investigators regarding the presence of LP. Four degrees of severity of the condition were distinguished. Degrees of severity of LP as well as numbers of affected individuals increased as a function of age ($p < 0.001$). LP occurred more frequently in males than females ($p = 0.0029$). In addition, smoking exerted a positive influence on the prevalence ($p < 0.05$), and a positive correlation appeared between mouth burning and LP ($p < 0.01$).

Introduction

Fissured tongue (lingua plicata; LP) is a common normal variant or sign of age of the tongue surface, which does not require treatment (CESKO ET AL. 2006). Clinically, fissures of varying depth up to 6 mm sometimes extending to the margin are apparent on the dorsal surface of the tongue (DU TOIT 2006, SILVERMAN ET AL. 2001). Mostly, a central longitudinal furrow (median sulcus) initially develops in the middle of the dorsum of the tongue (EISEN 1998). The deeper this median sulcus, the more numerous transversal furrows radiate from it (CESKO ET AL. 2006). Extensive furrows can be connected with each other (DU TOIT 2006), making the tongue look like composed of separate lobes (KELSCH ET AL. 2014). The condition is confined to the anterior two-thirds of the tongue which are of ectodermal origin,

whereas the endodermal base (radix) of the tongue located behind the sulcus terminalis is spared (CESKO ET AL. 2006).

Diagnosis is made on the basis of a clinical examination, biopsies are rarely taken. For the examination the tongue is protruded in such a way that the fissures unfold and become visible (SILVERMAN ET AL. 2001). The prevalence of LP in the general population is reported to be 10 to 20 per cent (DARWAZEH & ALMELAIH 2011, GÖNÜL ET AL. 2011, JAHANBANI ET AL. 2009, PATIL ET AL. 2013). Children under 4 years of age exhibit fissured tongue only as an exception, and in less than 10-year-olds the prevalence amounts to less than 2 per cent (JÄRVINEN ET AL. 2014, SHULMAN 2005). In general, LP occurs more frequently in males than females (DARWAZEH & ALMELAIH 2011, PATIL ET AL. 2013) and increases strikingly with increasing age in both genders (JÄRVINEN ET AL.

2014, JAHANBANI ET AL. 2009, REICHART 2000). Sometimes LP occurs in combination with a geographic tongue (CESKO ET AL. 2006, JOSEPH & SAVAGE 2000).

Typically, LP is clinically asymptomatic (DU TOIT 2006, ROGERS & BRUCE 2004). Also secretion and composition of saliva are normal (KULLAA-MIKKONEN ET AL. 1985). If fissures are deep enough that food residues are entrapped in them and persist, an inflammation can ensue (DARWAZEH & ALMELAIH 2011). In this case, the patient should be informed about the harmlessness of the condition (KELSCH ET AL. 2014) and instructed about correct tongue cleansing (DU TOIT 2006, SILVERMAN ET AL. 2001).

The etiology of LP is not completely known yet (SILVERMAN ET AL. 2001). A polygenic or autosomal dominant hereditary component is presumed, because LP clusters in families with other affected individuals. However, the difference in prevalence observed in various age groups suggests that LP primarily is not of genetic origin (JÄRVINEN ET AL. 2014).

Smoking constitutes a risk factor for many oral mucosal lesions and in particular also for LP (AL-ATTAS ET AL. 2014). Benign tobacco-associated alterations of the oral mucosa most notably are smoker's melanosis (brownish hyperpigmentation of the keratinized gingiva) and smoker's leukokeratosis (smoker's palate). Oral leukoplakia is considered the most important precancerosis. When affecting the squamous epithelium, it constitutes a potentially life-threatening alteration of the oral mucosa (BORNSTEIN ET AL. 2006). Besides, the risk of mouth carcinomas is increased as a result of chronic alcohol consumption (SINGER & TEYSSEN 1999).

The best known cause of LP is age. An additional factor influencing the development of LP is hyposalivation which in turn is also associated with age (PATIL ET AL. 2013). In humans with trisomy 21, LP is frequently observed in childhood (AL-MAWERI ET AL. 2015, BILGILI ET AL. 2011). In addition, LP particularly often occurs in individuals wearing a removable denture (GÖNÜL ET AL. 2011) as well as in cases of psoriasis or following an oncological therapy (NISA & GIGER 2012, ZARGARI 2006). Also, individuals suffering from granulomatous inflammatory diseases frequently exhibit LP. In particular, fissured tongue is invariably present as part of the Melkersson-Rosenthal syndrome which constitutes a form of orofacial granulomatosis and is characterized by the triad of recurrent orofacial swelling, recurrent facial palsy, and LP (CESKO ET AL. 2006, ROGERS 1996). However, an orofacial granulomatosis can also be an oral manifestation of a systemic disease, in particular of sarcoidosis or Crohn's disease (BLANK ET AL. 2014, GRAVE ET AL. 2009).

In the anterior two-thirds the dorsum of the human tongue is covered by specialized keratinized mucosa (JOSEPH & SAVAGE 2000). Healthy tongues exhibit filiform and fungiform papillae. The histological appearance of LP differs from that of a healthy tongue (JÄRVINEN ET AL. 2014). Investigations have shown that not only the epithelium, but also the lamina propria and musculature are involved in the formation of fissures (CESKO ET AL. 2006, ROGERS & BRUCE 2004). In cases of LP, the number of inflammatory cells is markedly elevated in the entire mucosa of the dorsum of the tongue (KULLAA-MIKKONEN ET AL. 1985, KULLAA-MIKKONEN & SORVARI 1986). Filiform papillae at the surface of the tongue persist, those in deeper fissures can be missing as a result of the bacterial inflammation (KELSCH ET AL. 2014, ROGERS & BRUCE 2004). In cases of LP, the lamina propria is also thickened (DU TOIT 2006, KELSCH ET AL. 2014). In addition, the upper muscle cells are slender and separated (JÄRVINEN ET AL. 1991). The smooth surface on the inside of the fissures exhibits scattered abortive papillae (CESKO ET AL. 2006, ROGERS & BRUCE 2004).

Despite a number of publications on LP, it has never been explicitly examined, from what age on this variant of the tongue occurs with increased frequency. The primary target parameter of the present study was the age from which LP occurs more often. As secondary parameters, the associations of LP with smoking, alcohol consumption, mouth burning, and wearing of a denture were investigated.

Materials and Methods

In the course of the present study, 1,000 patients from a dental practice in St. Gall (Switzerland) were examined within a period of 8 months. At the start of sampling, consecutive patients without preselection were asked upon reception, whether they would participate in the study. Thereafter, only those individuals were invited who fitted the study design with respect to age (Tab. I). Voluntary participation in the study was integrated at the dentist's visit. All participants completed a written declaration of consent. For individuals of less than 18 years of age, parents' consent was obtained as well. The observational study was approved by the ethical committee of St. Gall (EKSG Nr: 13/132). The clinical examination, taking of photographs, and the completion of the questionnaire were always carried out by the same investigator (the first author).

The study participants from 0 to 99 years of age were classified into 10 age groups. A group comprised all patients of a particular decade of life. Numbers of patients per age group were set according to the percentage of the respective age group in the Swiss resident population. These data were obtained from the Swiss Federal Statistical Office in 2011 (Tab. I).

Together with the investigator, patients completed a questionnaire containing information regarding age and gender. Because of the negative effects of bad habits on the oral cavity, patients were asked whether alcohol was consumed (daily or occasionally) and whether they smoked. The presence of a removable denture was ascertained clinically, because prosthesis carriers in comparison to patients without prostheses exhibit a significantly elevated prevalence of oral mucosal lesions (JAINKITTIVONG ET AL. 2002, LIN ET AL. 2001). Finally, patients were asked about possible tongue burning (Tab. II). Excluded from the study were patients following radiotherapy or chemotherapy as well as individuals suffering from Melkersson-Rosenthal

Tab. I Composition of the study sample corresponding to the Swiss population in the year 2011

Age	Age category	Total 7,954,662	Percentage	Number in study
0-10	0	861,608	11	110
11-20	1	877,785	11	110
21-30	2	1,032,732	13	130
31-40	3	1,110,174	14	140
41-50	4	1,291,094	16	160
51-60	5	1,049,864	13	130
61-70	6	847,371	10	100
71-80	7	546,549	7	70
81-90	8	291,599	4	40
91-100	9	45,093	1	10

Tab. II Summary of possible findings and statements

Gender	Female	Male		
Smoking	Non-smoker	Smoker		
Alcohol	Never	Occasionally	Daily	
Removable denture	No	Yes		
Mouth burning	No	Yes		
Lingua plicata	Grade 0 = no LP	Grade 1 = tongue visible in the fissures	Grade 2 = partly smooth squamous epithelium (without visible tongue papillae) in the fissures	Grade 3 = smooth squamous epithelium in the fissures at all locations (middle, side, margin)
Location middle, side or margin	No LP	Middle	Side	Margin

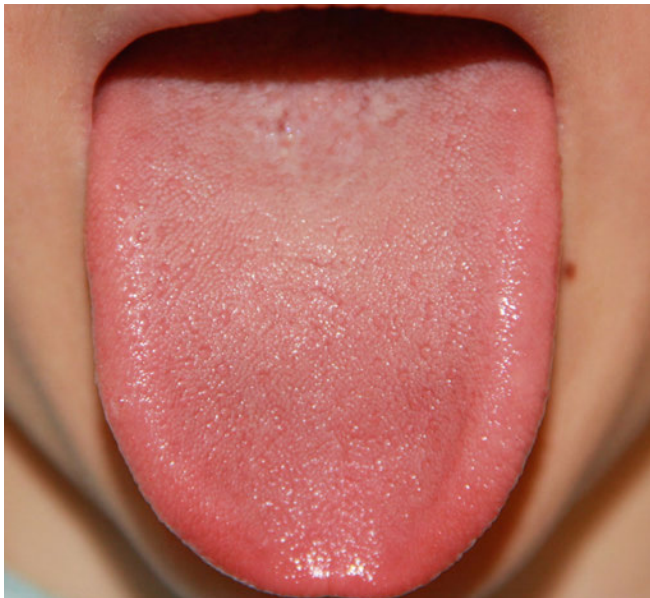

Fig. 1 Grade 0 = no fissured tongue

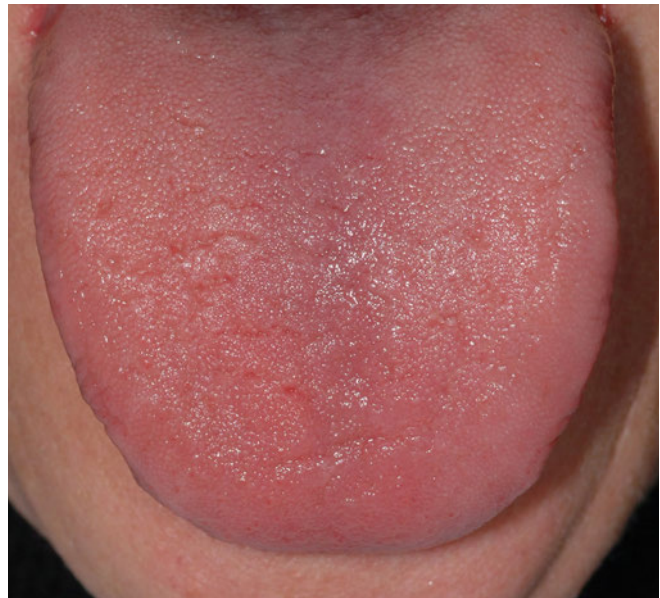

Fig. 2 Grade 1 = tongue papillae visible in the fissures

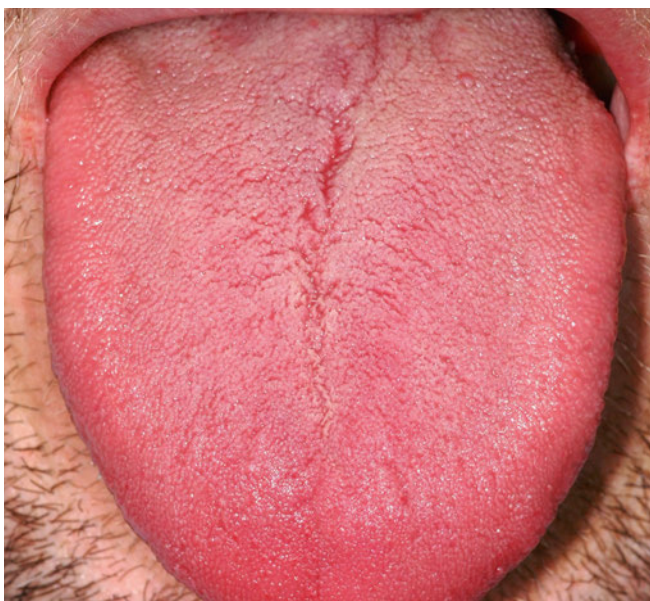

Fig. 3 Grade 2 = partly smooth squamous epithelium (without visible tongue papillae) in the fissures along the middle, on the side, or on the margin of the tongue (at the maximum in two locations)

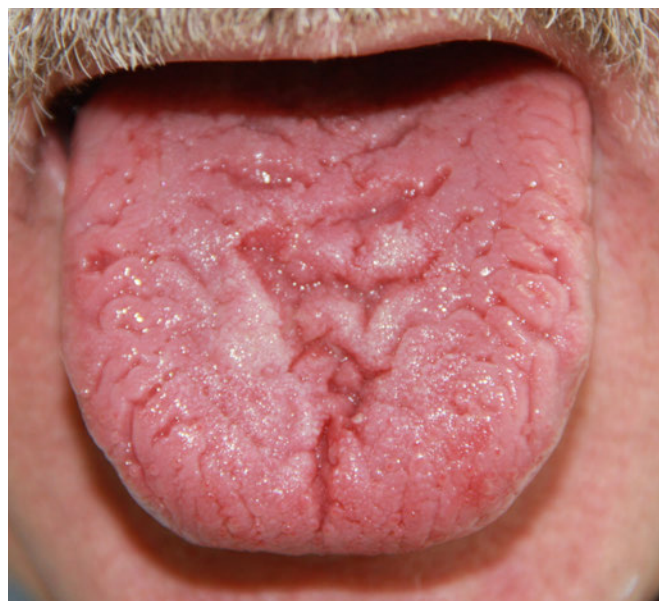

Fig. 4 Grade 3 = smooth squamous epithelium in the fissures along the middle, on the side, and on the margin of the tongue

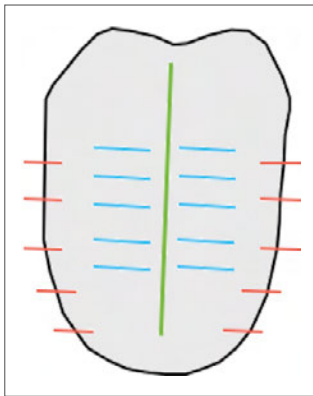


Fig. 5 Graphical representation of the locations of fissures along the middle (green), on the side (blue), and on the margin (red) of the tongue. This served as the basis for the classification into grades.

syndrome, which constitute the most frequent causes of non-age-associated LP. Further possible exclusion criteria such as trisomy 21 or acromegaly did not occur in the patient sample examined.

A color photograph of the protruded tongue was taken (Canon EOS 40D with EF-S 18–135 mm 3.5–5.6 IS lens). The faces of the participants could not be recognized on the pictures. Diagnosis of LP was made on the basis of the photographs which were viewed full-screen always on the same computer monitor (iMac 27 inches) and evaluated by two dentists independently. Calibration of the investigators in the course of a preliminary test was accomplished based on photographs from the University of Basel. In cases of divergent ratings by the investigators ($n=76$), photographs were once more viewed together and assigned to a degree of severity. The main target parameter was the age from which LP occurs with significantly increased frequency. Secondary parameters were the associations of LP with smoking, alcohol consumption, mouth burning, and wearing of prostheses. Fissures were classified into four degrees (Figs. 1–4). If fissures were visible with the naked eye, the tongue was assigned to a grade from 1 to 3. Starting with grade 2 no papillae were visible anymore in deeper fissures and

only smooth squamous epithelium could be recognized. As soon as this occurred in the middle, on the side, and on the margin, the tongue was assigned to grade 3. In addition, the location of the fissure was recorded (Fig. 5).

After all the findings and statements of the investigation had been collected (Tab. II), data was statistically evaluated using ordinal logistic regression. The degree of severity of the tongue fissures constituted the dependent variable. Independent variables were age, gender, smoking, alcohol consumption, and mouth burning (R CORE TEAM 2014).

Results

Among the total of 1,000 patients examined, 465 were males and 535 females. The age of the individuals ranged from 0 to 96 years (the average age was 41.3 years). 206 patients smoked, 598 consumed alcohol occasionally, and another 83 daily. 68 patients were wearing a dental prosthesis and 17 confirmed to sometimes suffer from mouth burning. 732 participants (361 males and 371 females) revealed LP. Grade 1 was observed in 488 patients, grade 2 in 173, and grade 3 in 71 individuals. In 646 patients there was at least a fissure along the midline. 62 of the 68 denture wearers revealed LP. 16 patients (16 after radiotherapy/chemotherapy and 0 because of Melkersson-Rosenthal syndrome) were excluded from the study prior to the clinical examination. The average age of individuals revealing grade 1 and grade 3 LP was 24.5 years and 66.4 years, respectively.

The four degrees of severity were associated with the age categories (Fig. 6). In 0- to 20-year-olds the proportion of grade 0 exceeded 50%. Starting from 20 years of age the proportion of grade 1 increased markedly. From the age category 7 to category 9, the frequency of grade 3 rose from 15% to 36%, and grade 0 was observed only in exceptional cases. Hence from the 80th year of life, LP of grades 2 or 3 was present in more than 70% of individuals. Overall, age correlated markedly with the occurrence of LP ($p<0.001$).

Also, the localization of LP as a function of age was examined. In younger individuals, fissured tongue was found rather isolat-

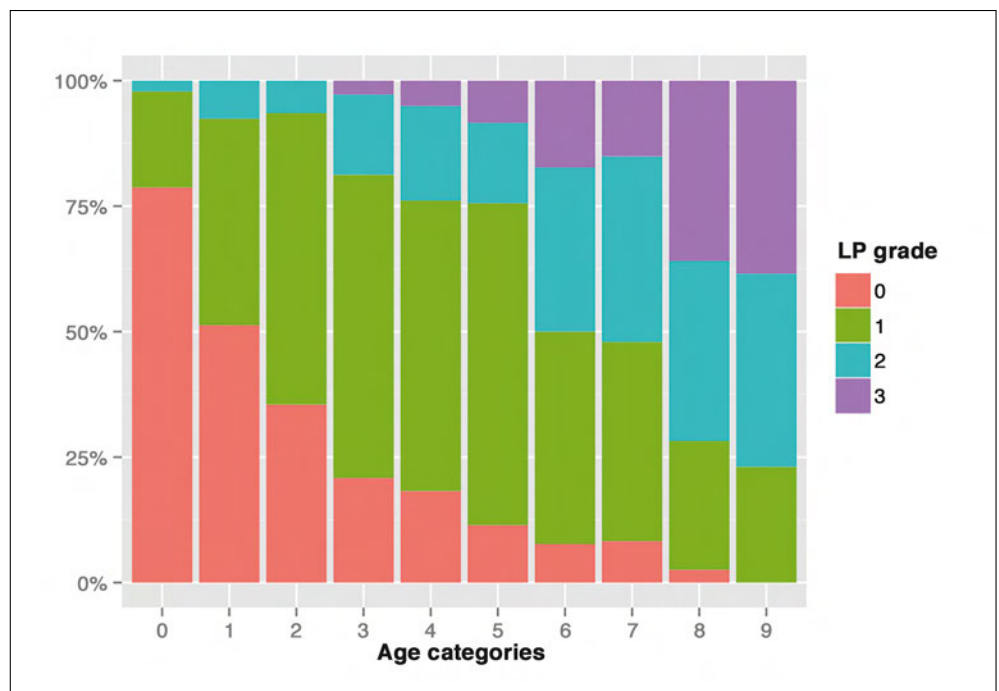


Fig. 6 Graphical representation of the four degrees of severity of LP in the age categories specified in Table I

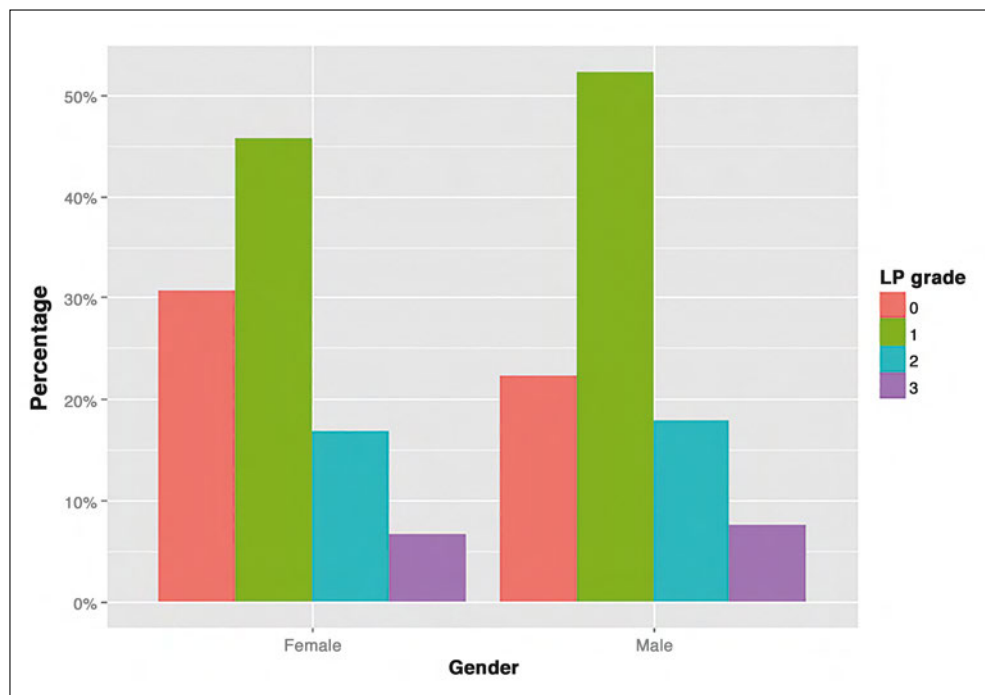


Fig.7 Graphical representation of the four degrees of severity of LP as against gender

ed in the middle of the tongue. The older the individuals the more frequently LP was observed on the entire dorsal tongue surface, i.e. in the middle, on the side, and on the margin (Fig. 5).

In comparison to females, males more often exhibited LP ($p=0.0029$; Fig. 7). In addition, smoking and mouth burning positively affected the presence of LP in the sample investigated ($p=0.02$ related to smoking, $p=0.0028$ related to mouth burning). As far as alcohol consumption and wearing of a removable denture were concerned, no differences between patients with and without LP could be detected.

Discussion

Since the clinical appearance of LP and the pattern of fissures vary markedly, it is difficult to classify LP into degrees of severity and to define a threshold above which a tongue fissure should be considered LP. In the present sample, LP was observed in 73% of individuals (grade 1 in 49%, grade 2 in 17%, grade 3 in 7%). The prevalence considerably exceeded that found in previous studies. For the classification in this investigation, deliberately no minimum in depth or length of fissures was used. As soon as a fissure could be recognized with the naked eye, it was classified into grades 1 to 3. If our classification, similar to that in other studies, had started with a fissure depth at which only smooth squamous epithelium was visible (grade 2), a prevalence of 24% would have emerged. In previous investigations, varying definitions were used. Some authors only considered tongue fissures of at least 2mm in depth and extending over more than a third of the dorsal tongue surface (DARWAZEH & ALMELAIH 2011). Other investigators in turn also took into account smaller varieties such as fissures along the midline, which resulted in a prevalence of over 20% (KOVAC-KAVCIC & SKALERIC 2000).

Evidence that LP constitutes a sign of age, on the one hand, is the average age of participants with LP of grade 3, which strikingly exceeded that of participants without LP or with LP of grade 1. On the other hand, the frequency of LP increased with age, and a tendency could be recognized that the degree

of severity of LP (grade 0 to grade 3) also rose with increasing age. Almost 40% of the more than 90-year-olds revealed LP of grade 3.

Several oral lesions tend to develop more rapidly and more frequently in elderly individuals. Reasons for this tendency are a reduced immune response, a diminished repair capacity of the DNA, and the age-associated atrophy of oral tissues, in particular of epithelia and the salivary glands (REICHART 2000). The prevalence of LP increases significantly at ages over 59 years (DARWAZEH & ALMELAIH 2011). In over 70-year-olds, authors even reported a frequency of more than 37% (JAINKITTIVONG ET AL. 2002).

Various previous studies showed a gender difference in the prevalence of LP. Some investigators observed an only slightly more frequent occurrence in males (KELSCH ET AL. 2014, PATIL ET AL. 2013), whereas others found a strikingly increased frequency of LP in males (DARWAZEH & ALMELAIH 2011). In other studies, however, females were affected more often (VIEIRA-ANDRADE ET AL. 2011, BÀNÖCZY ET AL. 1993). The present data record confirms the proposition that males exhibit LP significantly more frequently ($p=0.0029$). Grade 0 occurred in only 10% of males, but in 16% of females.

In the present study, 80% of smokers showed LP. In other investigations the proportion amounted to about 27% (AL-ATTAS ET AL. 2014). Tobacco consumption probably does not lead directly to LP. The correlation could also be attributed to gender, because more males than females smoke. On the other hand, the effect could also be due to age. The majority of smoking participants in the present sample was aged over 30 years.

Also regarding mouth burning, the correlation with LP could be indirect. Reasons could be systemic diseases or the fact that mouth burning also occurs more often at old age. In this study, 17 patients complained of mouth burning. This resulted in a significant association with LP ($p=0.0028$).

The present data record did not reveal an association of LP and alcohol consumption. Alcohol consumption is assumed to lead to pathologic alterations of the oral mucosa, but not to be responsible for the occurrence of LP. In addition, alcohol-in-

duced alterations largely concern the floor of the mouth and the retromolar area.

Wearing of dental prostheses is associated with an elevated prevalence of oral mucosal lesions. Among these, LP is the most frequent alteration (KOVAC-KAVCIC & SKALERIC 2000, LIN ET AL. 2001). The same conclusion was also reached by other authors who, however, acknowledged that prosthesis carriers are generally older and, hence, this association in fact could be due to the correlation with age (JAINKITTIVONG ET AL. 2002). Although in the present sample, 62 out of the 68 prosthesis carriers exhibited LP, this did not entail a significant correlation of LP with wearing of a denture. The statistical regression analysis suggested that other features such as age were responsible for the connection. Thus, the correlation with LP was indirect. Wearing of a dental prosthesis was not discriminating with respect to the occurrence of LP. It could be worthwhile to conduct specific investigations in prosthesis carriers using controlled groups of similar age classes.

Of relevance for the general dentist is the fact that LP is observed frequently and requires no specific therapy, unless it is part of an orofacial granulomatosis. If symptoms arise as a result of a plaque-related inflammation, oral hygiene measures should be instructed (tongue cleansing).

The present study was carried out using randomly selected patients from a dental practice. The distribution of age categories

was representative for the Swiss population. In order to preclude regional peculiarities, additional studies in other regions of Switzerland possibly are necessary.

Résumé

La langue plicaturée (LP) se caractérise par des sillons et fissures de profondeurs variables sur la face dorsale de la langue. Cette altération est habituellement asymptomatique. La prévalence déclarée est généralement de 10 à 20% mais il y a là de grandes différences.

La présente étude examine sur un groupe de 1000 patients (n=465 hommes, n=535 femmes) la relation entre une LP et l'âge des patients ainsi que d'autres facteurs. Les participants ont rempli un questionnaire donnant des informations sur leur sexe, âge, consommation d'alcool et de tabac, le port éventuel de prothèses dentaires et les brûlements de bouche. Puis une photo de la langue a été faite. Les photos ont été examinées et classées en quatre niveaux différents d'altération.

La manifestation d'une LP ainsi que le nombre de personnes concernées augmentent avec l'âge ($p < 0,001$). Chez les hommes, une LP est plus fréquente que chez les femmes ($p = 0,0029$).

Fumer a également une influence positive sur la prévalence ($p < 0,05$) et on constate une corrélation positive entre les brûlements de bouche et une LP ($p < 0,01$).

References

- AL-ATTAS S A, IBRAHIM S S, AMER H A, DARWISH Z S, HASSAN M H: Prevalence of potentially malignant oral mucosal lesions among tobacco users in Jeddah, Saudi Arabia. *Asian Pac J Cancer Prev* 15: 757-762 (2014)
- AL-MAWERI S A, TARAKJI B, AL-SUFYANI G A, AL-SHAMIRI H M, GAZAL G: Lip and oral lesions in children with Down syndrome. A controlled study. *J Clin Exp Dent* 7: 284-288 (2015)
- BĀNŌCZY J, RIGÒ O, ALBRECHT M: Prevalence study of tongue lesions in a hungarian population. *Community Dent Oral Epidemiol* 21: 224-226 (1993)
- BILGILI S G, AKDENİZ N, KARADAG A S, AKBAYRAM S, CALKA O, ÖZKOL H U: Mucocutaneous disorders in children with Down syndrome: case-controlled study. *Genet Couns* 22: 385-392 (2011)
- BLANK J, RAFFAUF A, WÖLBER J, RATKA-KRÜGER P: Orofaziale Granulomatose – ein seltenes aber zahnärztlich relevantes Krankheitsbild. *Swiss Dent J* 124: 1062-1063 (2014)
- BORNSTEIN M M, KLINGLER K, SAXER U P, WALTER C, RAMSEIER C A: Tabakassoziierte Veränderung der Mundhöhlenschleimhaut. *Schweiz Monatsschr Zahnmed* 116: 1261-1269 (2006)
- ČESKO E, JANSEN T, DISSEMOND J, ESSER S, HELBIG D, GRABBE S: Faltzunge (Lingua plicata). *hautnah dermatologie* 1: 17-18 (2006)
- DARWAZEH A M, ALMELIAH A A: Tongue lesions in a Jordanian population. Prevalence, symptoms, subject's knowledge and treatment provided. *Med Oral Patol Oral Cir Bucal* 16: 745-749 (2011)
- DU TOIT G: Clinical allergy images. *Curr Allergy Clin Immunol* 19: 30-31 (2006)
- EISEN D P, LYNCH D P: The mouth: diagnosis and treatment. Mosby, St. Louis, pp 73-79 (1998)
- GÖNÜL M, GÜL U, KAYA I, KOÇAK O, ÇAKMAK S K, KILIÇ A, KILIÇ S: Smoking, alcohol consumption and denture use in patients with oral mucosal lesions. *J Dermatol Case Rep* 4: 64-68 (2011)
- GRAVE B, MCCULLOUGH M, WIESENFELD D: Orofacial granulomatosis – a 20-year review. *Oral Dis* 15: 46-51 (2009)
- JAHANBANI J, SANDVIK L, LYBERG T, AHLFORS E: Evaluation of oral mucosal lesions in 598 referred Iranian patients. *Open Dent J* 3: 42-47 (2009)
- JAINKITTIVONG A, ANEKSUK V, LANGLAIS R P: Oral mucosal conditions in elderly dental patients. *Oral Dis* 8: 218-223 (2002)
- JÄRVINEN J, KULLAA-MIKKONEN A M, PESONEN E: Histological study of inflamed tongue mucosa. *Scand J Dent Res* 99: 424-430 (1991)
- JÄRVINEN J, MIKKONEN J J, KULLAA A M: Fissured tongue: a sign of tongue edema. *Med Hypotheses* 82: 709-712 (2014)
- JOSEPH B K, SAVAGE N W: Tongue pathology. *Clin Dermatol* 18: 613-618 (2000)
- KELSCH R D, JAMES W D, ORTONNE J P, WELLS M J, EISEN D, QUIRK C M: Fissured tongue. *Medscape Reference* (2014)
- KOVAC-KAVCIC M, SKALERIC U: The prevalence of oral mucosal lesions in a population in Ljubljana, Slovenia. *J Oral Pathol Med* 29: 331-335 (2000)
- KULLAA-MIKKONEN A, TENOVUO J, SORVARI T: Changes in composition of whole saliva in patients with fissured tongue. *Scand J Dent Res* 93: 522-528 (1985)
- KULLAA-MIKKONEN A, SORVARI T: Lingua fissurata: a clinical, stereomicroscopic and histopathological study. *Int J Oral Maxillofac Surg* 15: 525-533 (1986)
- LIN H C, CORBET E F, LO E C: Oral mucosal lesions in adult Chinese. *J Dent Res* 80: 1486-1490 (2001)
- NISA L, GIGER R: Lingua plicata. *Can Med Assoc J* 184: E241 (2012)
- PATIL S, KASWAN S, RAHMAN F, DONI B: Prevalence of tongue lesions in the Indian population. *J Clin Exp Dent* 5: 128-132 (2013)
- R CORE TEAM: R: A language and environment for statistical computing. R Foundation for Statistical Computing, R version 3.0.3 (2014-03-06). URL: <https://www.r-project.org>. Vienna (2014)
- REICHAERT P A: Oral mucosal lesions in a representative cross-sectional study of aging Germans. *Community Dent Oral Epidemiol* 28: 390-398 (2000)
- ROGERS R S, BRUCE A J: The tongue in clinical diagnosis. *J Eur Acad Dermatol Venereol* 18: 254-259 (2004)
- ROGERS R S: Melkersson-Rosenthal syndrome and orofacial granulomatosis. *Dermatol Clin* 14: 371-379 (1996)
- SHULMAN J D: Prevalence of oral mucosal lesions in children and youths in the USA. *Int J Paediatr Dent* 15: 89-97 (2005)
- SILVERMAN S, EVERSOLE L R, TRUELOVE E L: Essentials of oral medicine. 1st ed., PMPH, USA, pp 252-259 (2001)
- SINGER M V, TEYSSEN S: Alkohol und Alkoholfolgekrankheiten: Grundlagen – Diagnostik – Therapie. 1. Aufl., Springer-Verlag, Heidelberg, pp 348-349 (1999)
- VIEIRA-ANDRADE R G, ZUQUIM GUIMARAES F F, VIEIRA C S, FREIRE S T, RAMOS-JORGE M L, FERNANDES A M: Oral mucosa alterations in a socioeconomically deprived region: prevalence and associated factors. *Braz Oral Res* 25: 393-400 (2011)
- ZARGARI O: The prevalence and significance of fissured tongue and geographical tongue in psoriatic patients. *Clin Exp Dermatol* 31: 192-195 (2006)